

MRI – Key evidence

Neonatal MRI/MRI at near term equivalent age with neuroanatomical abnormalities predictive of cerebral palsy:

- 86-89% Sensitivity
- 89% Specificity

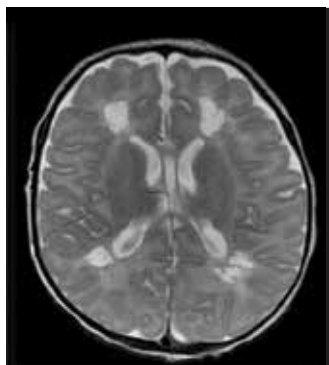
**ABNORMAL
NEURO
IMAGING**



NB: Normal MRI findings do not preclude the clinical diagnosis of cerebral palsy, as 10% infants with cerebral palsy have normal MRI findings.

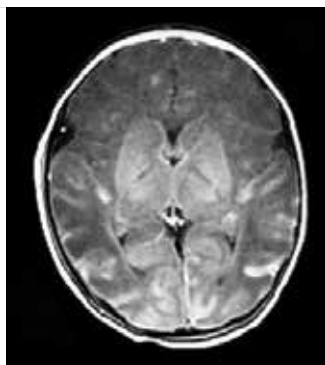
CITATION	EVIDENCE	#STUDIES	#PATIENTS	ACCURACY FOR CEREBRAL PALSY	QUALITY
Ashwal 2009	Clinical Guide	10	644	Sensitivity = 89%	14/14
Bosanquet 2013	Systematic Review	3	702	Sensitivity = 86% Specificity = 89%	14/14
Ment 2002	Clinical Guide	13	410	Basal ganglia injury = CP predictive (50-94%) MRI = predictive DWI = probably predictive MRS = possibly predictive	14/14

The most predictive MRI patterns are:



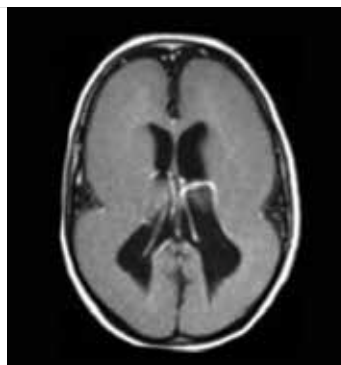
Predominant white matter injury [cystic periventricular leukomalacia (PVL) or periventricular haemorrhagic infarctions] (56%)

IMAGE 1



Cortical and deep grey matter lesions [basal ganglia/thalamus lesions, watershed injury (parasagittal injury), multicystic encephalomalacia, stroke] (18%)

IMAGE 2



Brain maldevelopments [lissencephaly, pachygyria, cortical dysplasia, polymicrogyria, and schizencephaly] (9%)

IMAGE 3

IMAGES 1 AND 2 PROVIDED BY ASSOCIATE PROFESSOR ANDREA GUZZETTA AND DR SIMONA FIORI FROM THE UNIVERSITY OF PISA

IMAGE 3 PROVIDED BY DR CATHY MORGAN, CEREBRAL PALSY ALLIANCE RESEARCH INSTITUTE.

Systematic review of the evidence indicates that MRI has a higher sensitivity than CT (89% versus 77%) and is therefore the preferred neuroimaging modality.^{1,2}

MRI findings also help predict the likely presumed timing of the brain abnormality and pathogenesis of the insult.

Adapted with permission from: Novak et al 2017. Early, Accurate Diagnosis and Early Intervention in Cerebral Palsy. *JAMA Pediatr.* 2017;171(9):897-907. doi:10.1001/jamapediatrics.2017.1689
Available from: <http://jamanetwork.com/journals/jamapediatrics/article-abstract/2636588>

