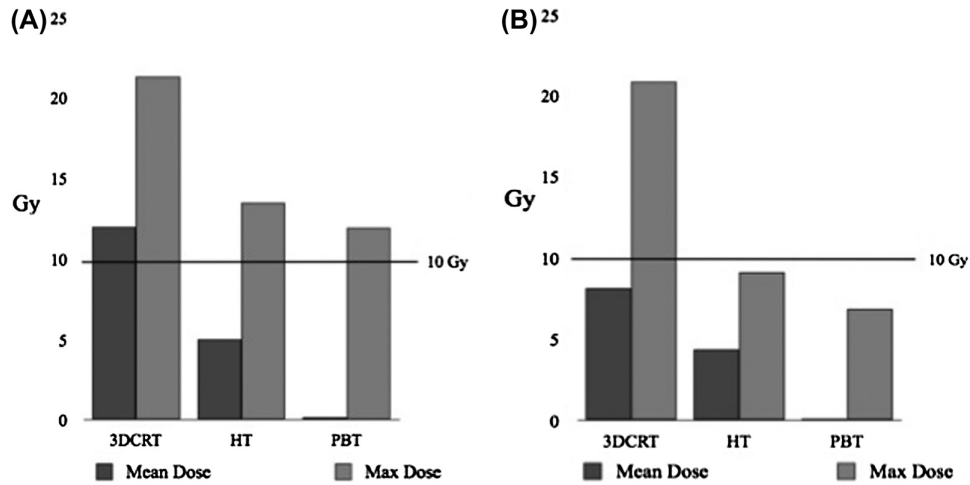


*Supplementary material for* Brower J. V. et al. Proton therapy and helical tomotherapy result in reduced dose deposition to the pancreas in the setting of cranio-spinal irradiation for medulloblastoma: Implications for reduced risk of diabetes mellitus in long-term survivors. *Acta Oncol* 2015;54:522–6.



Supplementary Figure 1. Graphical dosimetric comparison. (A) Whole pancreas maximum and mean doses. (B) Pancreatic tail maximum and mean doses. 10 Gy reference point for comparison.