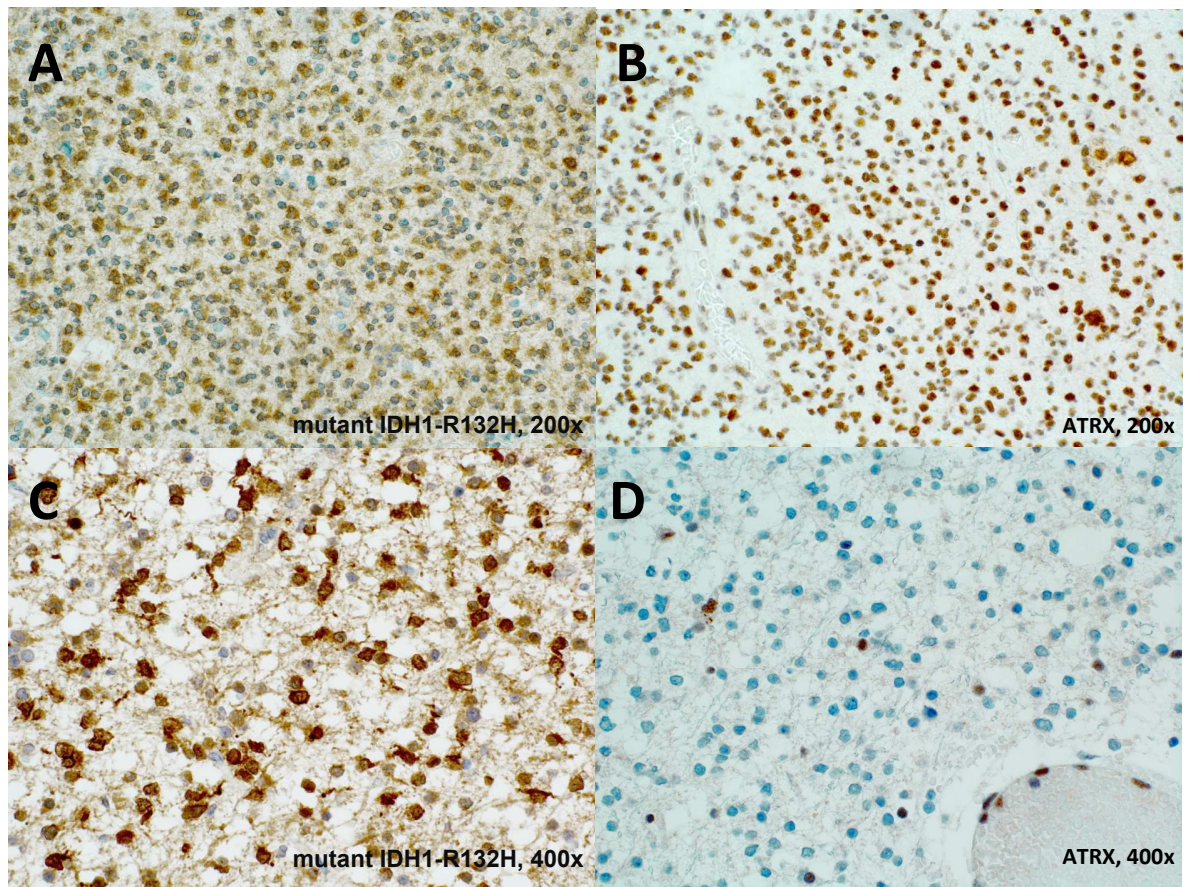


Supplemental Figure



Supplemental Figure. Positive control for mutant IDH1-R132H and negative control for ATRX immunohistochemical staining.

Solitary oligodendroglioma (WHO grade II), with IDH-mutant, 46 years old male (A, B).

Solitary diffuse astrocytoma (WHO grade II), with mutant IDH R132H, 35 years old male (C, D).